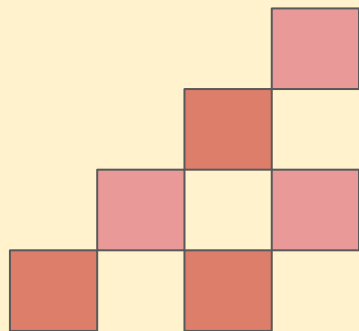


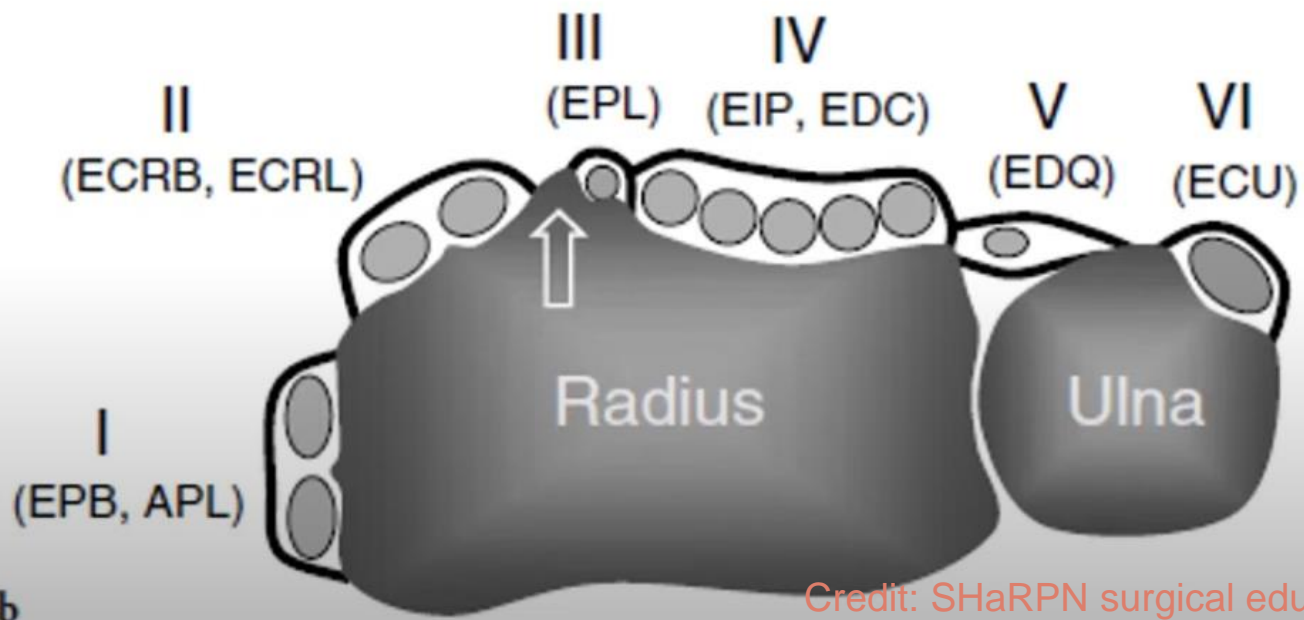


# Hand Extensor Tendon Injuries


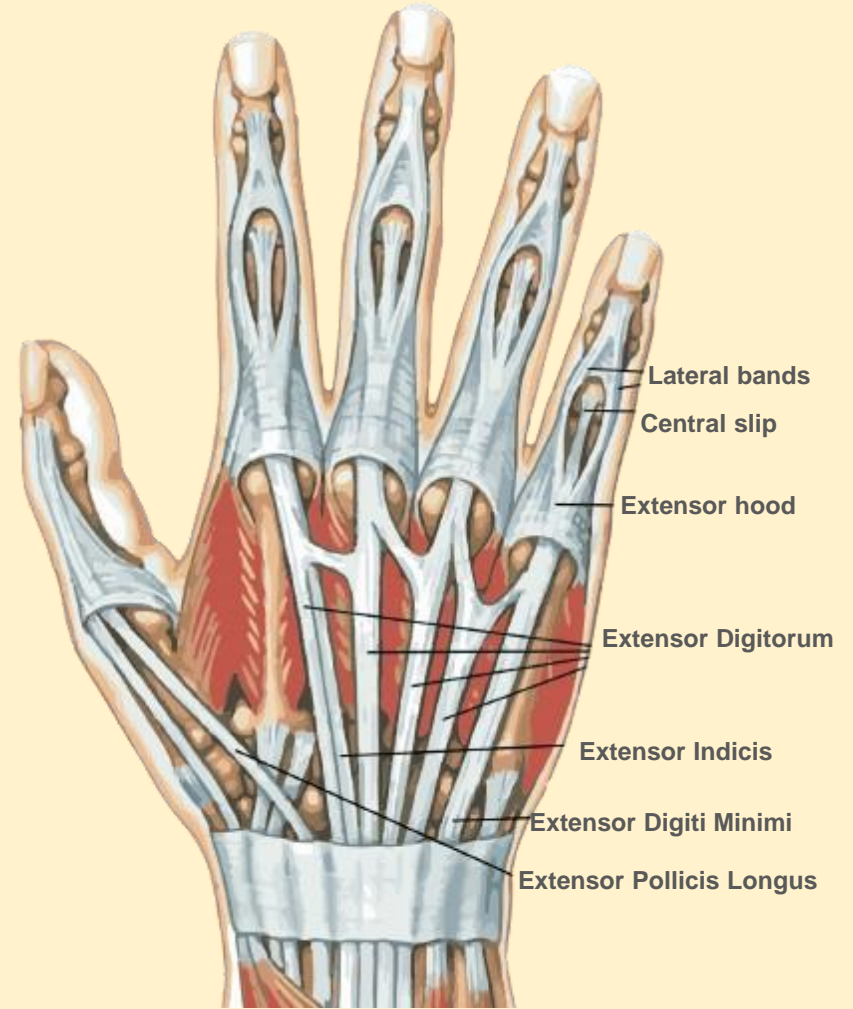
Vladislav Chalenko, DMSc, PA-C



# Extensor compartments



Credit: SHaRPN surgical education



# Zone specific considerations

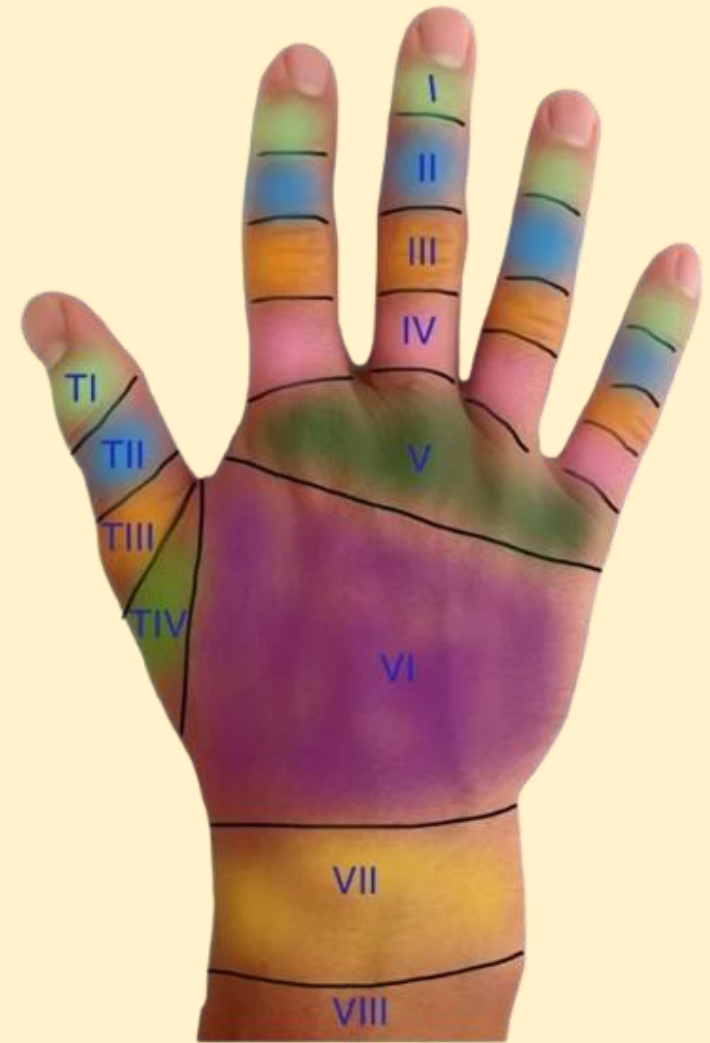The more distal the injury, the more time under immobilization.

Zone III - Evaluate central slip.

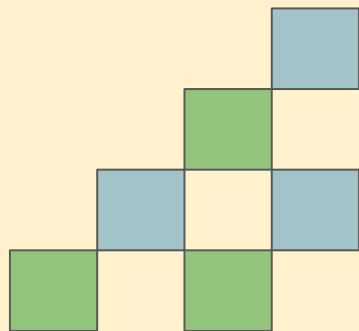
Zone V - Consider “Fight bite”

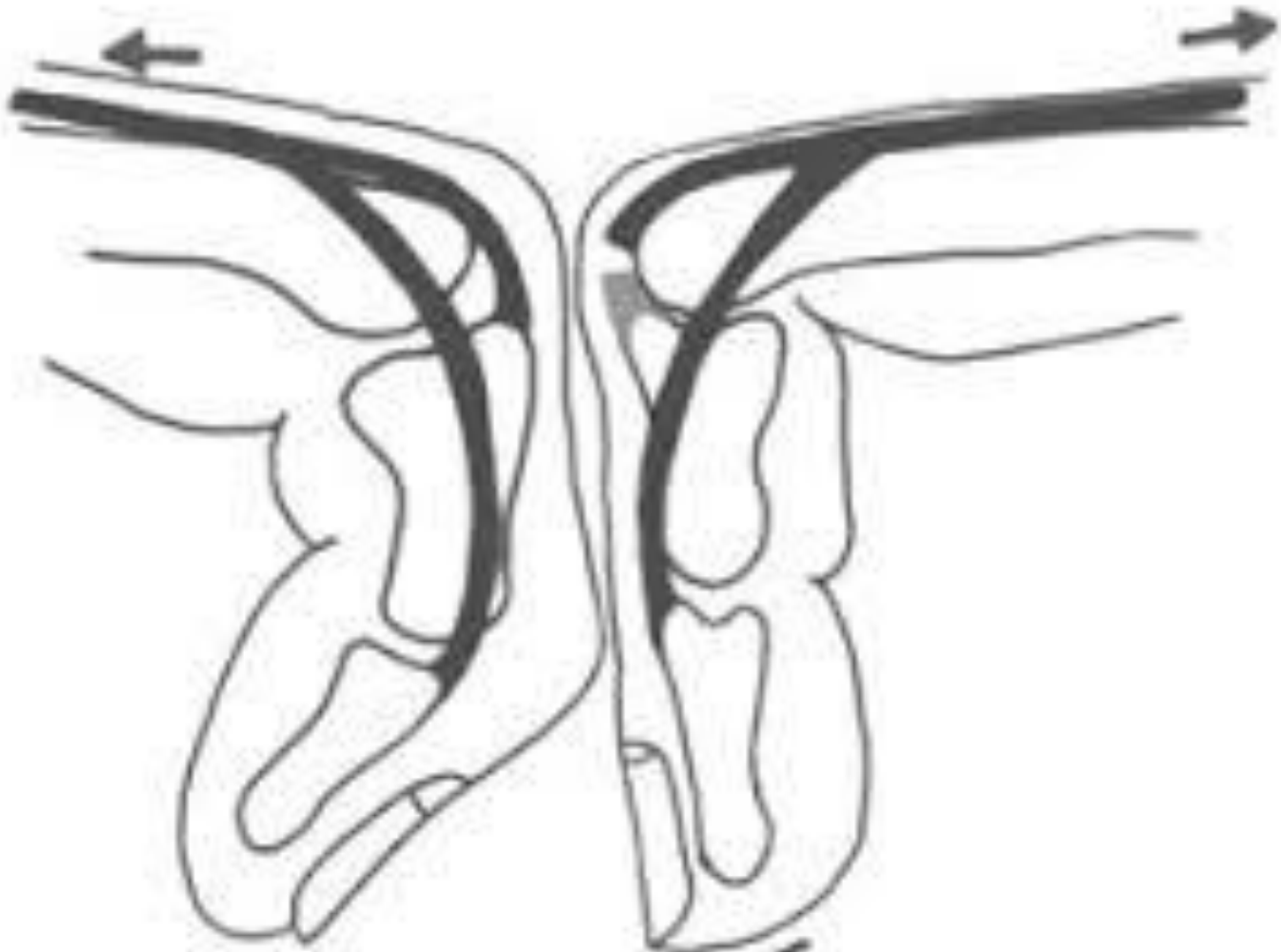
Proximal Zone VI - Look closely for superficial radial n. and dorsal ulnar n.

Remember that the 2nd and 5th digits have two extensors.



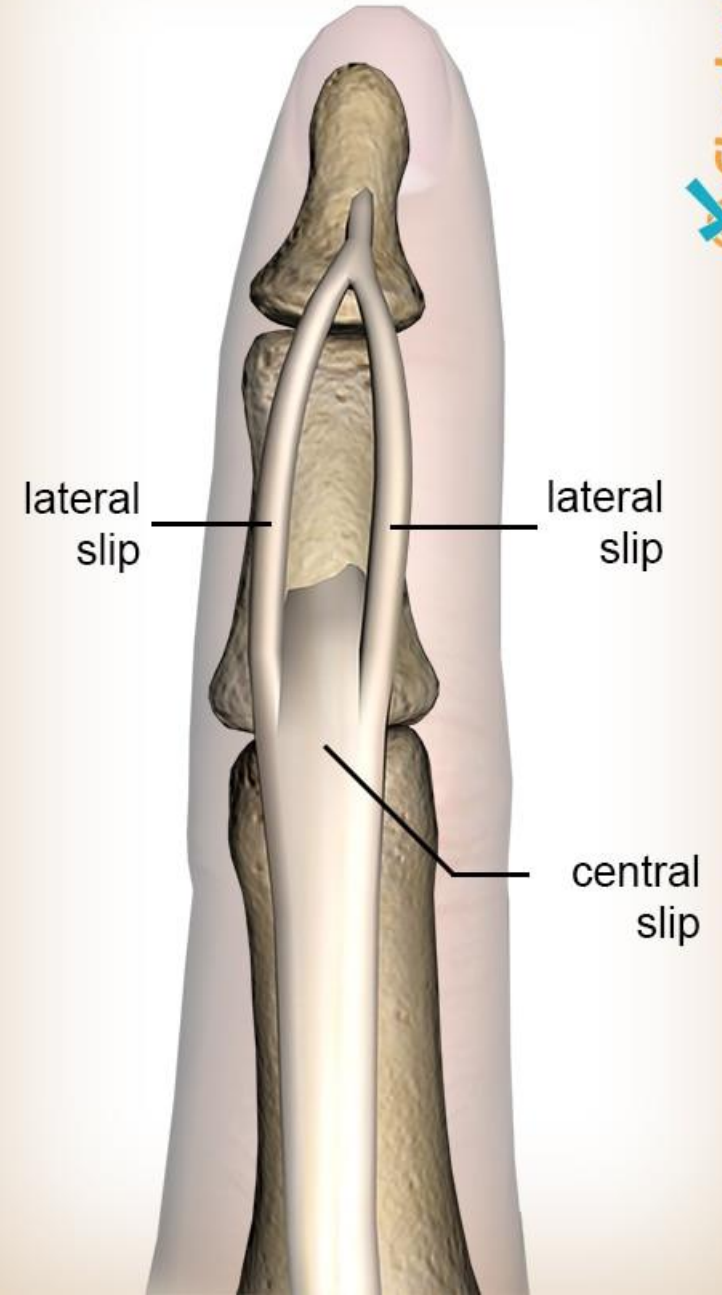
Credit: Brian Lin, MD





Schreuders TA, Soeters JN, Hovius SE, Stam HJ. A Modification Of Elson's Test For The Diagnosis Of An Acute Extensor Central Slip Injury. *The British Journal of Hand Therapy*. 2006;11(4):111-112. doi:10.1177/175899830601100402

## Finger extensor tendon





# The ideal physical exam

**Hyperextension test**

**Elson's test (central slip) and modified**

**MCP in extension**

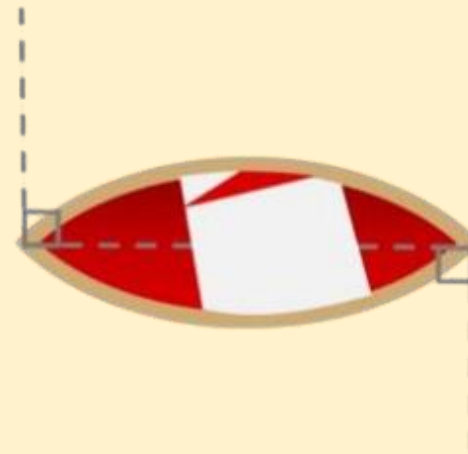
**Examine each joint against resistance (DIP, PIP, and MCP)**

**Neurovascular exam: sensation, color, capillary refill**

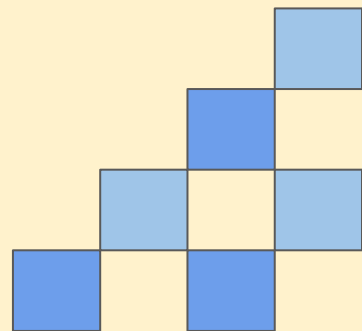
**Good lighting, bloodless field**

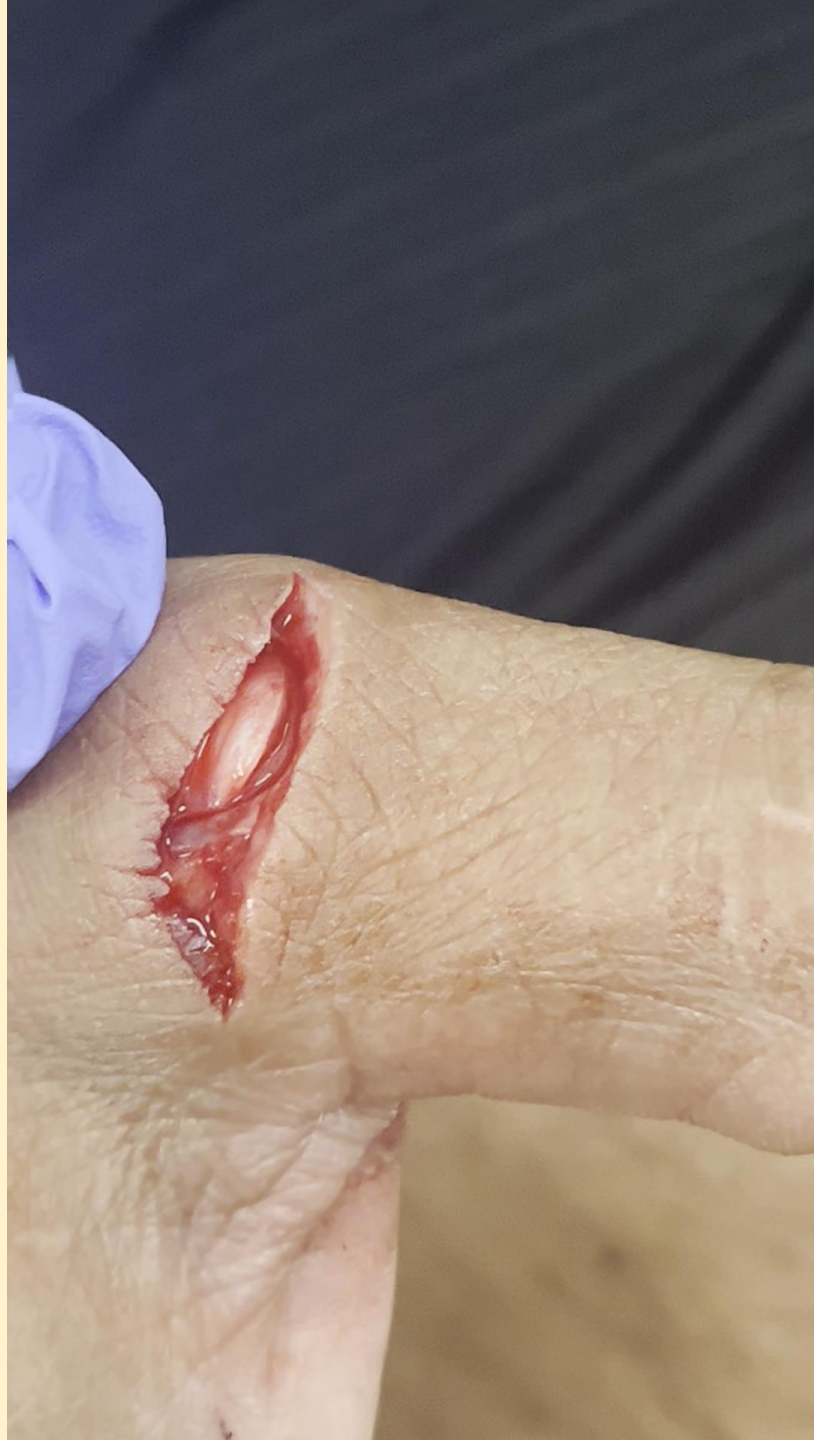
**Compare to opposite hand**

**Extend wound if required**



*Credit: David Ting and Academic Life in Emergency Medicine*







# When to refer without repair?

**Zone VII and zone VIII**

**Involvement of the thumb**


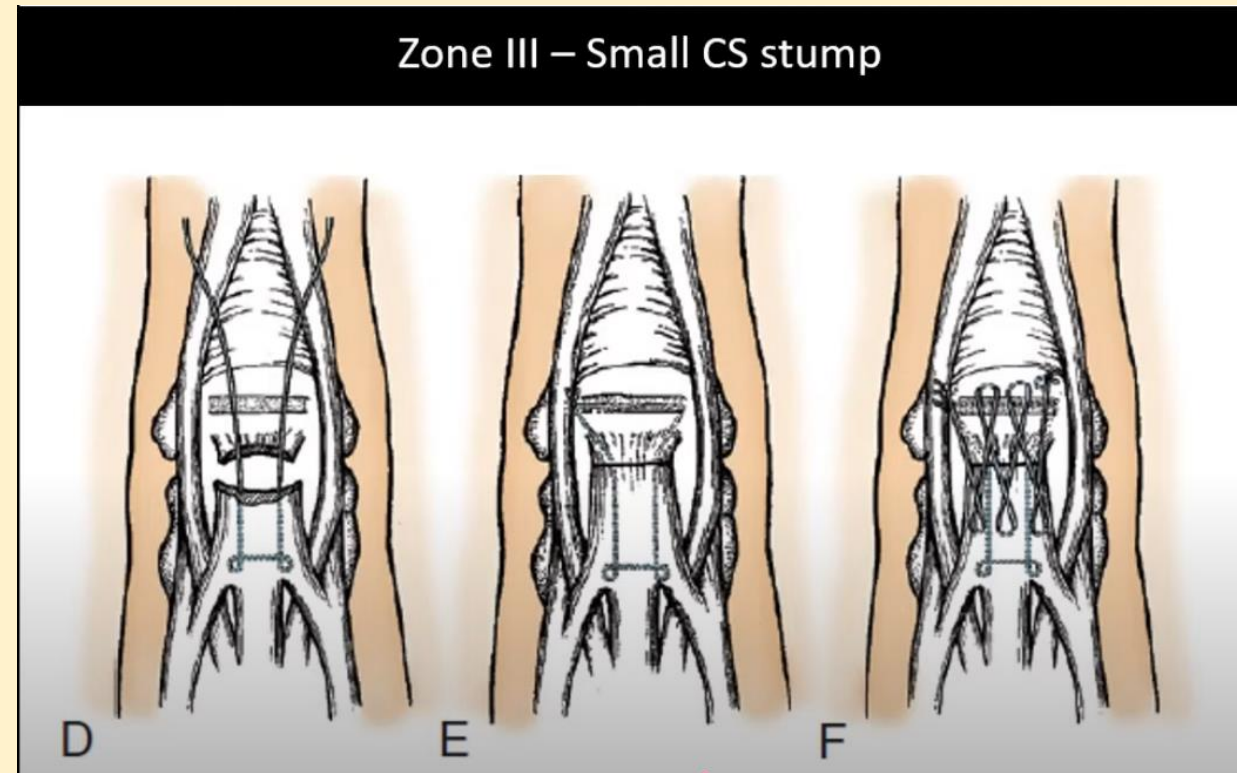
**Neurovascular complication, open fracture, or gross joint capsule violation**


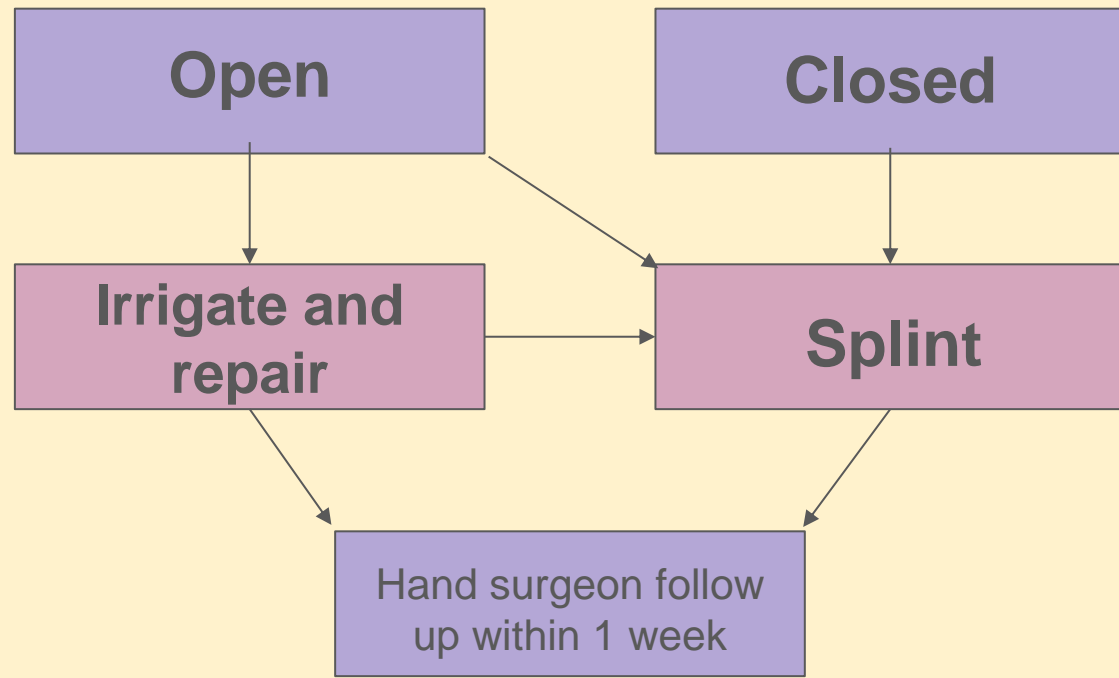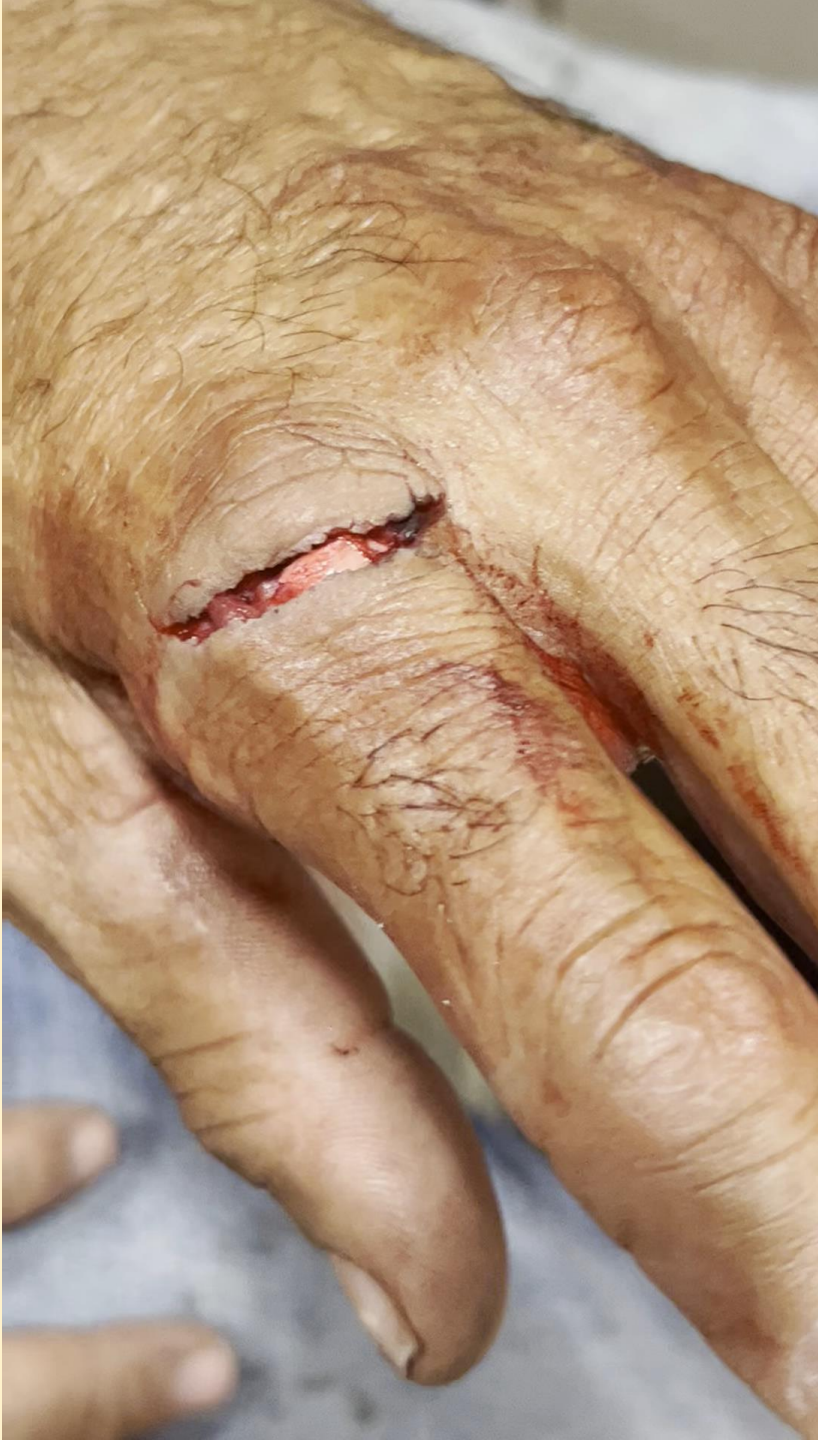
**Zone III injuries with short stump →**

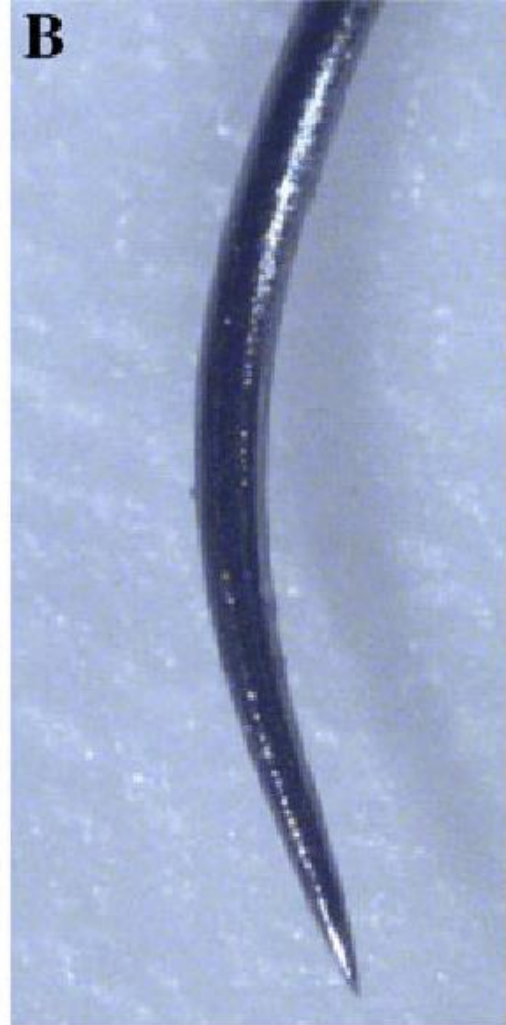**High risk of infection**

**Elite athletes, pianists, etc**

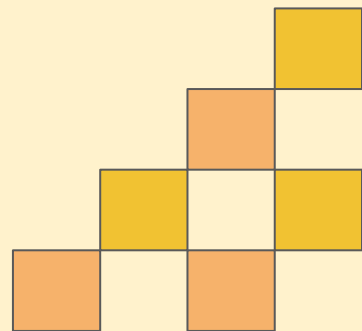

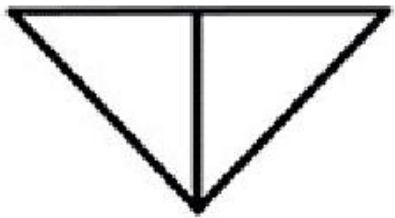
**Any time you are not comfortable**

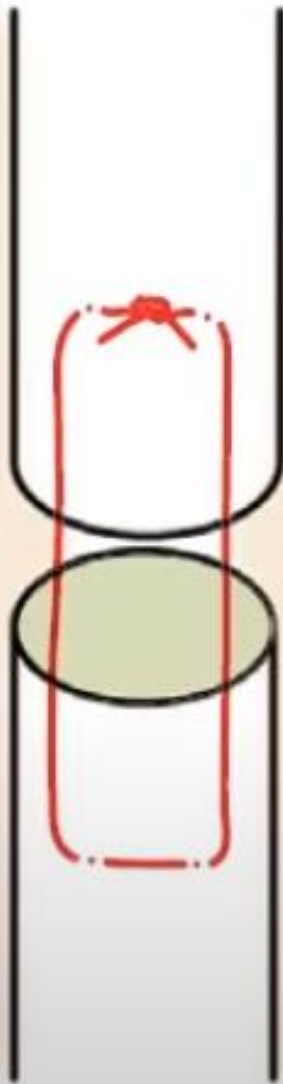






Easy rule: 3-0 for hand, 4-0 for fingers





Mattress

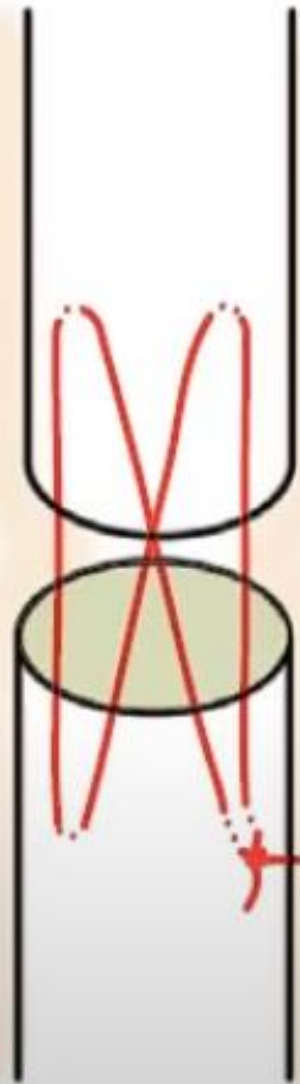
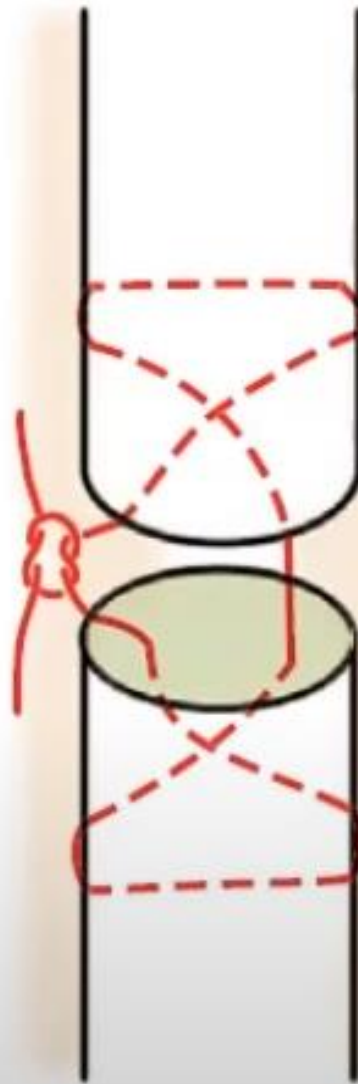
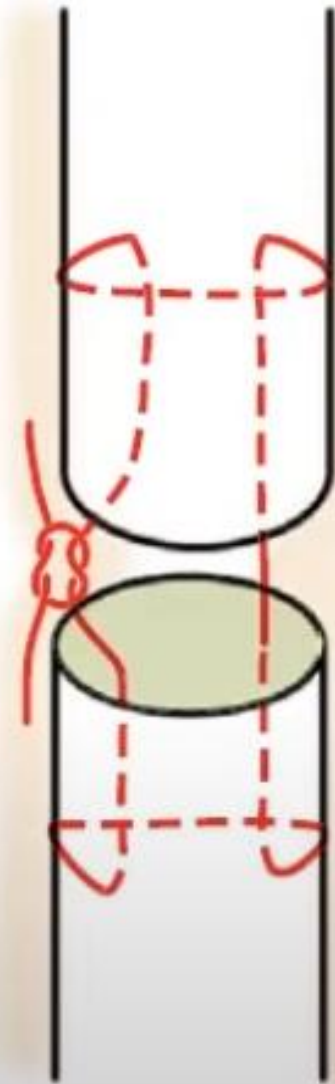


Figure 8

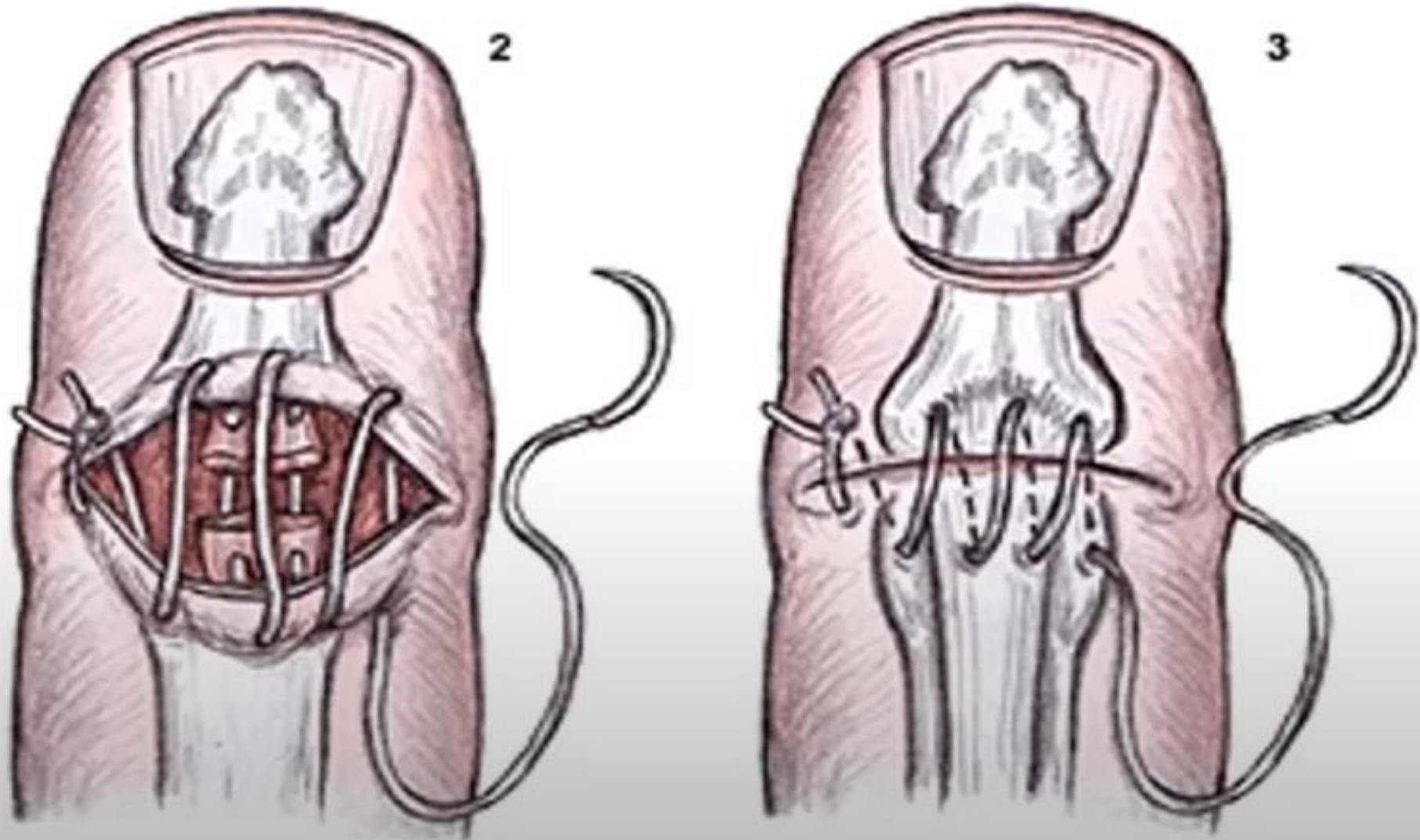


Modified  
Bunnell



Modified  
Kessler

# Tenodesis



# Works Cited

1. Prichard R. Open extensor tendon repair in the ED. *Brown Emergency Medicine Blog*. November 28, 2022. Accessed February 10, 2025. <https://brownemblog.com/blogposts/2021/4/5/open-extensor-tendon-repair-in-the-ed>.
2. Calabro JJ, Hoidal CR, Susini LM. Extensor tendon repair in the emergency department. *J Emerg Med*. 1986;4(3):217-25. doi: 10.1016/0736-4679(86)90045-4. PMID: 3543112.
3. Ting D, Baylis J. Extensor tendon injuries of the hand: Emergency department management. *Academic Life in Emergency Medicine*. July 18, 2016. Accessed February 10, 2025. <https://www.aliem.com/extensor-tendon-injuries-hand/>.
4. Powell J, Lin B. Extensor tendon lacerations to the foot. *Academic Life in Emergency Medicine*. September 11, 2017. Accessed February 10, 2025. <https://www.aliem.com/extensor-tendon-lacerations-foot/>.
5. Yoon AP, Chung KC. Management of Acute Extensor Tendon Injuries. *Clin Plast Surg*. 2019 Jul;46(3):383-391. doi: 10.1016/j.cps.2019.03.004. Epub 2019 Apr 16. PMID: 31103083.
6. Chapter 76. Extensor Tendon Repair. In: Reichman EF. eds. *Emergency Medicine Procedures*, 2e. The McGraw-Hill Companies; 2013. Accessed February 10, 2025. <https://accessemergencymedicine.mhmedical.com/content.aspx?bookid=683&sectionid=45343717>
7. Colzani G, Tos P, Battiston B, Merolla G, Porcellini G, Artiaco S. Traumatic Extensor Tendon Injuries to the Hand: Clinical Anatomy, Biomechanics, and Surgical Procedure Review. *J Hand Microsurg*. 2016;8(1):2-12. doi:10.1055/s-0036-1572534
8. Rawson S, Cartmell S, Wong J. Suture techniques for tendon repair; a comparative review. *Muscles Ligaments Tendons*