

THE DIZZY PATIENT

Otologic evaluation

By: Christine B. Taylor, MD

LEARNING OBJECTIVES

After reviewing this module, the student will have the ability to:

- Develop a broad working diagnosis of the dizzy patient
- Evaluate the dizzy patient by physical exam and know when to refer for advanced testing
- Gain a basic understanding of inner ear anatomy and physiology
- Understand when the dizzy patient warrants consultation to Otolaryngology

CASE PRESENTATION

52 year old female with hypertension is referred to the ENT clinic for dizziness.
Patient reports that she gets dizzy spells several times per week.

These spells last seconds, and she describes the episodes as feeling like the room is spinning around her. The dizziness seems to be brought on by changes in position, specifically turning her head to the right or rolling over in bed to her right side. The dizzy spells seem to resolve on their own after several seconds.

No associated neurologic symptoms.

Patient denies hearing loss, otalgia, otorrhea, aural fullness, tinnitus.

Denies noise exposure, ear trauma, prior ear surgery, or family history of hearing loss.

What is your differential diagnosis?



DIFFERENTIAL DIAGNOSIS

There is a very broad differential for Dizziness: “VITAMIN C” mnemonic

-Vascular

- Orthostatic hypotension
- Cardiac arrhythmias, valve stenosis
- Brainstem cerebrovascular disease
- Migraine

-Infectious

- Labyrinthitis – postviral
- Meningitis

-Traumatic

-Autoimmune

-Metabolic/Medications:

- Diabetes
- Thyroid disease
- Aging

-Idiopathic/Iatrogenic

- Psychiatric/hyperventilation
- Vasovagal

-Neoplastic

- Cerebellopontine Angle Tumors (Vestibular schwannoma)

-Congenital

-Other:

- Medications
 - Medication side effects
 - Ototoxicity

-Otologic (Vestibular) causes

- Benign Paroxysmal Positional Vertigo (BPPV)
- Meniere’s disease

ETIOLOGIES OF DIZZINESS

- Dizziness is most common presenting complaint in patients 75 years or older
- Postural stability/balance involves integration of input from various systems:
 - Visual + Proprioceptive + Somatosensory + Vestibular (Inner ear)
- Majority (~90%) of dizziness can be attributed to one of the following categories:
 - Peripheral Vestibular disorders
 - Cardiovascular disorders
 - Multisensory disorders
 - Brainstem cerebrovascular disease
 - Neurologic disorders
 - Psychiatric disease
 - Hyperventilation syndrome

CHARACTERIZING DIZZINESS

- **Types of Dizziness**
 - Presyncope: impending faint, often describe 'spots' in vision
 - Dysequilibrium: impaired balance and gaze
 - Nonspecific: Light-headedness, fogginess, confusion
 - **Vertigo**: perception of motion (either linear or rotating) in absence of movement
- **Timing**
 - Less than 1 minute
 - Due to peripheral vestibular system/BPPV
 - Minutes to hours
 - Meniere disease, transient cerebral hypoperfusion, migraine, psychiatric disorders, otic syphilis
 - Hours to days
 - Migraine, Meniere, labyrinthitis

QUESTION

In our patient, after completing full history and physical, what physical exam or test will help point to an inner ear etiology in diagnosing this patient's dizziness?

- A. Audiogram/hearing test
- B. Tuning fork exam
- C. Pneumatic otoscopy
- D. Changing patient's posture/positioning on the exam table
- E. Neurologic exam, especially focusing on cranial nerves
- F. MRI

QUESTION

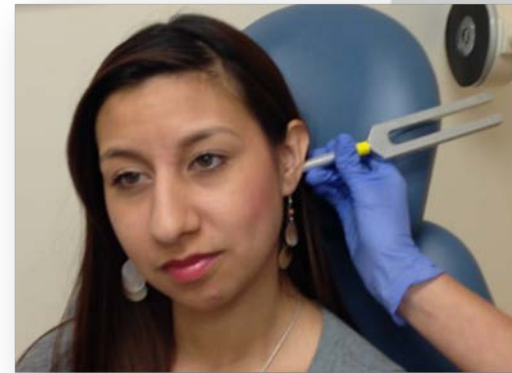
In our patient, after completing full history and physical, what physical exam or test will help point to an inner ear etiology in diagnosing this patient's dizziness?

- A. Audiogram/hearing test
- B. Tuning fork exam
- C. Pneumatic otoscopy
- D. Changing patient's posture/positioning on the exam table**
- E. Neurologic exam, especially focusing on cranial nerves
- F. MRI

All of the above are potentially important components of the workup of a dizzy patient, however postural testing will give the examiner an idea of vestibular function as it relates to this patient's dizziness

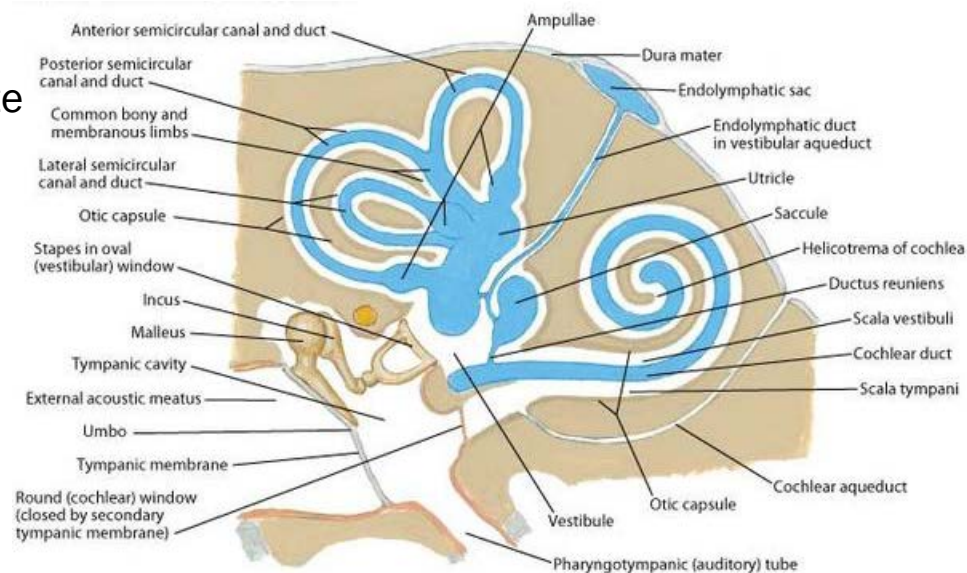
PHYSICAL EXAM

- Full neurologic exam
 - Test sensory, proprioceptive, cranial nerves, muscle strength, gait
- Cardiovascular
 - Ascultate, palpate pulses, orthostatics
- Otoscopy (under microscope if possible)
 - Rule out middle ear disease, cholesteatoma
- Tuning fork exam
- Head & Neck exam
- Eye exam/baseline visual exam
- Dix-Hallpike Maneuver



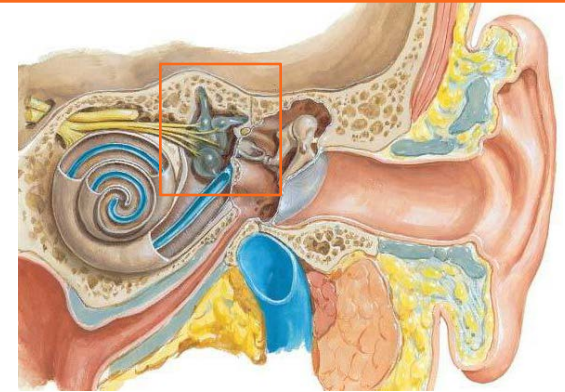
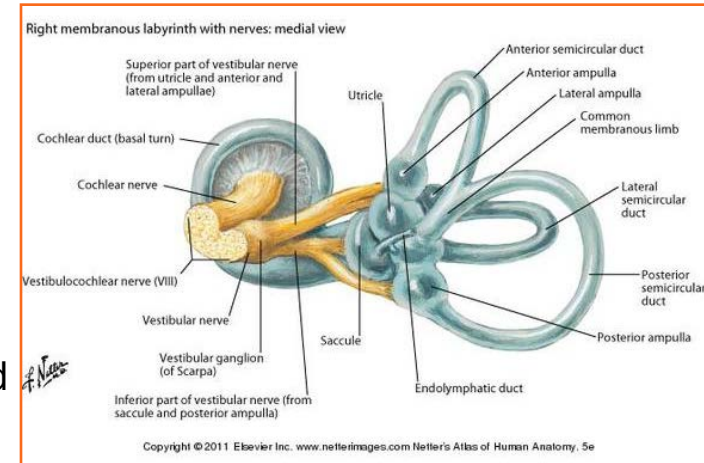
WORK UP OF VERTIGO

- **Comprehensive Hearing evaluation: Audiogram**
 - Associated Hearing loss or anatomic lesion related to vestibulocochlear nerve
- **Vestibular testing**
 - Formal vestibular testing helps localize defect and helps to differentiate vestibular pathology from ocular or proprioceptive deficits
- **MRI**
 - Neurologic deficit
 - Cerebellopontine Angle tumor



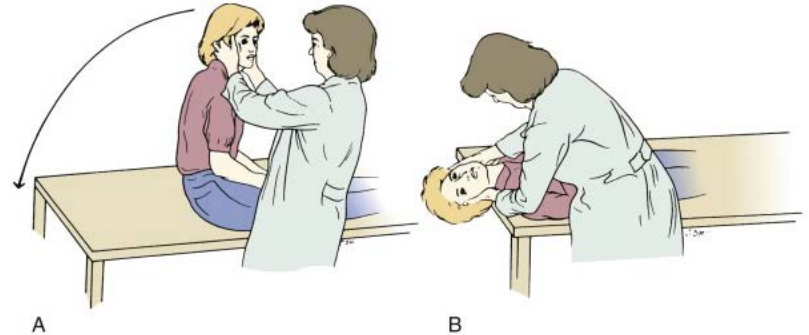
VESTIBULAR SYSTEM ANATOMY & PHYSIOLOGY

- Cranial Nerve VIII Vestibulocochlear nerve
- Components: 3 semicircular canals + 2 otoliths
- Orients head in space, detects motion to allow for positional adjustments of eyes, head, and posture to maintain vision and balance
- Semicircular canals detect angular acceleration (head rotation)
- Utricle + Saccule sensitive to linear accelerations (gravity, vehicle motion)
- Movement of endolymph with movement, shifting of otoconia in these organs stimulate hair cells that transmit information back to the brain



DIX-HALLPIKE

- Testing for reproduction of vertigo, as evidenced by nystagmus, with changes in position/head movements
- Rotation of head in plane of semicircular canal shifts canaliths, which causes overstimulation of nerves with overcorrection of eye position in opposite direction, producing nystagmus
- Positive Dix-Hallpike reproduces vertigo
 - Diagnostic of BPPV
- Our patient has a + Dix-Hallpike

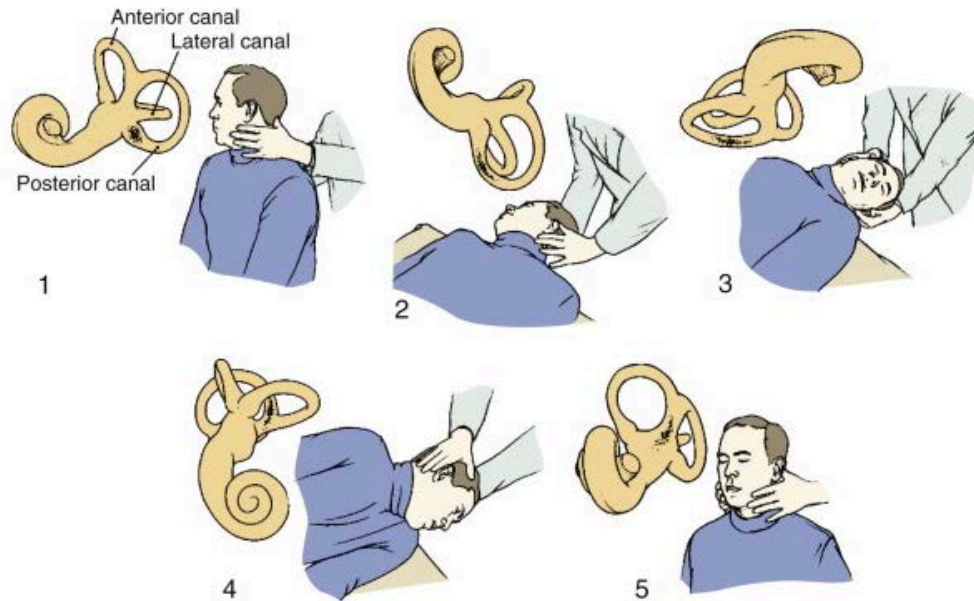


BENIGN PAROXYSMAL POSITIONAL VERTIGO

- **Most common peripheral vestibular disorder:** Typically presents in 4th-5th decade, 2:1 female predominance
- **Cause:** Otoliths accumulate in (most commonly posterior) semicircular canal → canalithiasis
- **Signs/symptoms:**
 - Vertigo spells associated with nystagmus lasting seconds that are precipitated by head movements such as rolling over in bed.
 - Nystagmus resolves with upright position.
- **Diagnosis**
 - Dix-Hallpike maneuver
 - Response to testing is fatigable, that is it decreases with repeated testing as the brain adjusts
- **Workup:** Full History & Physical, vestibular testing, Audiogram

TREATMENT OF BPPV

- Epley Maneuver: Cannalith repositioning
 - Cannalith travels through semicircular canal through series of rotational movements in the plane of canal to reach vestibule



MENIERE'S DISEASE

- **Also known as Idiopathic Endolymphatic Hydrops**
- Demographics: Peak age 4th & 5th decades, more prevalent in Caucasians, 1:1 male to female ratio, may be familial component
- **Cause: overaccumulation of endolymph within vestibular system**
- **Signs/symptoms**
 - Spontaneous episodic attacks of vertigo
 - Sensorineural hearing loss that fluctuates
 - Tinnitus +/- Aural fullness
- **Diagnosis**
 - Clinical history: Triad of Vertigo + Hearing loss + Tinnitus
 - Vestibular testing helpful

TREATMENT OF MENIERE'S

- **Medical Therapy**
 - Dietary Modifications: Restriction of Caffeine, Alcohol, Tobacco, and Salt (CATS)
 - Diuretics: decrease endolymph volume
 - Symptomatic treatment:
 - Antivertigo medications (ex. meclizine)
 - Antiemetics (ex. Promethazine, ondansetron)
 - Sedatives (ex. Benzodiazepines)
 - Antidepressants
- **Surgical treatment: Only after failure of medical management**
 - Intratympanic injection of steroids or ototoxic agents: “chemical labyrinthectomy”
 - Endolymphatic sac decompression
 - Nerve section
 - Labyrinthectomy : destruction of hearing and vestibular function

TAKE HOME POINTS

- There is an extremely broad differential diagnosis for Dizziness
- Rule out non-otologic causes of dizziness first
- Patients with vertigo should get comprehensive evaluation to include vestibular testing
- Know how to perform Dix-Hallpike Maneuver

RESOURCES

Bailey BJ, Johnson JT. Otolaryngology – Head & Neck Surgery. 4th ed. Lippincott Williams 2006.

Flint: Cummings Otolaryngology: Head & Neck Surgery, 5th ed. 2010 Mosby, especially ch 164-166

Netter F. Atlas of Human Anatomy. Accessed via The Netter presenter : human anatomy collection. edited by John T. Hansen. Elsevier 2010.

Images from Netter and Cummings (citations above)

ACKNOWLEDGEMENTS

Thank you to Christian Stallworth, MD for overseeing this project and providing advisory support.

Photo credits- Thank you to Megan M. Gaffey, MD and Lauren Thomas for providing physical exam photos

Editing and input:

Christopher Thompson, MD