

RHINOSINUSITIS

ACUTE, CHRONIC, SURGICAL AND NONSURGICAL MANAGEMENT

By: Christine B. Taylor, MD

LEARNING OBJECTIVES

After reviewing this module, the student will have the ability to:

- Correctly diagnose common nasal complaints, as well as acute and chronic sinusitis
- Be familiar with treatment strategies, both nonsurgical and surgical, for sinus disease
- Gain a basic knowledge of the anatomy of the nose and paranasal sinuses

CASE PRESENTATION

40 year old male presents to his primary care office with a chief complaint of “recurring sinus problems”.

He reports that his primary symptoms are stuffed/congested nose, and runny nose. He gets these episodes about twice per year, and states that it seems like they come on around the same time as if he can predict it, with an episode about every 6 months. Frequently, he is prescribed antibiotics from urgent care, and his symptoms resolve in 1-2 weeks.

What other questions should you ask?

CASE PRESENTATION

40 year old male presents to his primary care office with a chief complaint of “recurring sinus problems”.

On further questioning, patient reports that these episodes usually last a few weeks if untreated.

He also answers yes when you ask about sneezing, watery, itchy eyes and postnasal drainage. He reports a dry cough that occasionally will bring up some white mucous. He does report occasional sinus pressure with these episodes.

Denies fevers, tooth pain, loss of smell, changes in vision, creamy-yellow nasal drainage.

On exam, nasal mucosa is boggy and bluish with clear rhinorrhea.

What is your diagnosis?

QUESTION

How would you treat the above patient?

- A. Amoxicillin
- B. Nasal decongestants, such as pseudoephedrine
- C. Topical nasal steroids
- D. Augmentin (amoxicillin-clavulanate)
- E. Topical nasal vasoconstrictors

QUESTION

How would you treat the above patient?

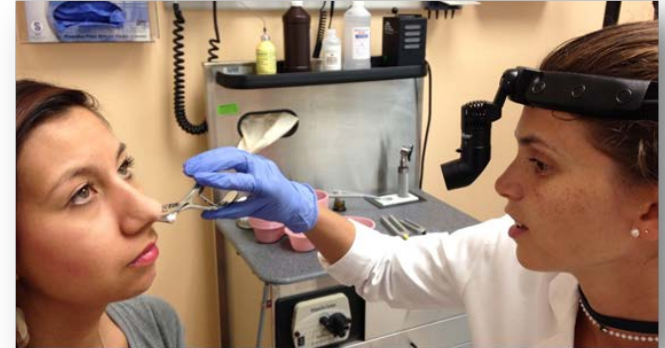- A. Amoxicillin
- B. Nasal decongestants, such as pseudoephedrine
- C. Topical nasal steroids
- D. Augmentin (amoxicillin-clavulanate)
- E. Topical nasal vasoconstrictors

This patient has classic seasonal allergic rhinitis symptoms: nasal congestion, clear rhinorrhea, postnasal drainage, itchy/watery eyes, sneezing, occurring at specific times of the year (for example, in this patient, spring and fall)

The mainstay of therapy for Allergic rhinitis is daily topical nasal steroid spray (fluticasone). He can also be started on oral antihistamines (cetirizine, loratadine). He should also be started on nasal saline irrigations (to be done prior to nasal steroids to prevent washing out of medication).

RHINITIS

- **Allergic Rhinitis (AR)**
 - Nasal + ocular symptoms
 - Type I hypersensitivity:
 - Antigen-specific IgE bind to mast cells
 - Histamine release and then trigger of inflammatory response
- **Non-allergic Rhinitis**
 - Infectious
 - Viral infections: rhinovirus, influenza, adenovirus
 - Vasomotor
 - Autonomic response to cold air or strong odors; parasympathetic vasodilation and mucosal edema
 - Irritation
 - Chemicals or inhaled irritants
 - Medication-related
 - Rhinitis medicamentosa: tachyphylaxis after prolonged use of topical alpha-blocking topical nasal decongestants (Afrin); rebound congestion
 - ACE Inhibitors, beta-blockers, OCPs, hormonal changes can all cause rhinitis



CASE PRESENTATION

57 year old female presents with a chief complaint of chronic recurring “sinus headaches”. Patient reports that over the past 5 years, she has several episodes per week of headache with forehead/sinus pressure and pain.

On further questioning, she denies nasal purulence, difficulty smelling, fevers/chills, tooth pain, changes in vision.

Denies allergy symptoms- no sneezing, itchy watery eyes, clear rhinorrhea, or nasal congestion.

CT sinus demonstrates well-aerated sinuses with minimal to no mucosal thickening.

Does this patient have nasal or sinus disease?

CASE PRESENTATION

57 year old female presents with a chief complaint of chronic recurring “sinus headaches”.

Does this patient have nasal or sinus disease?

This patient does not meet the criteria for acute or chronic sinusitis . She does not appear to have rhinitis.

Frontal headaches are often attributed to sinus pressure, however recent studies have demonstrated that up to 80% of these headaches are not related to sinus pathology, and that these headaches frequently respond to therapy directed at migraine headache.

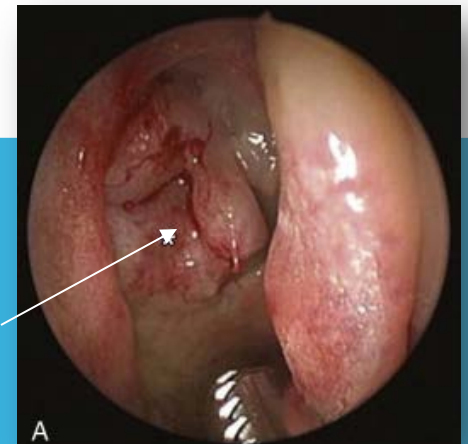
SINUSITIS

Acute Sinusitis

- 7-14 days to 1 month of symptoms
- Infectious etiology
 - Viral (rhinovirus, parainfluenza, RSV, influenza virus)
 - Bacterial (strep pneumo, H. flu, Moraxella catarrhalis)
- Symptoms: Purulent nasal drainage + facial pain/pressure + nasal obstruction
 - May also have recent onset hyposmia, fever, maxillary tooth pain, cough, headache
- Diagnosis: Primarily clinical diagnosis, based on time course and symptoms

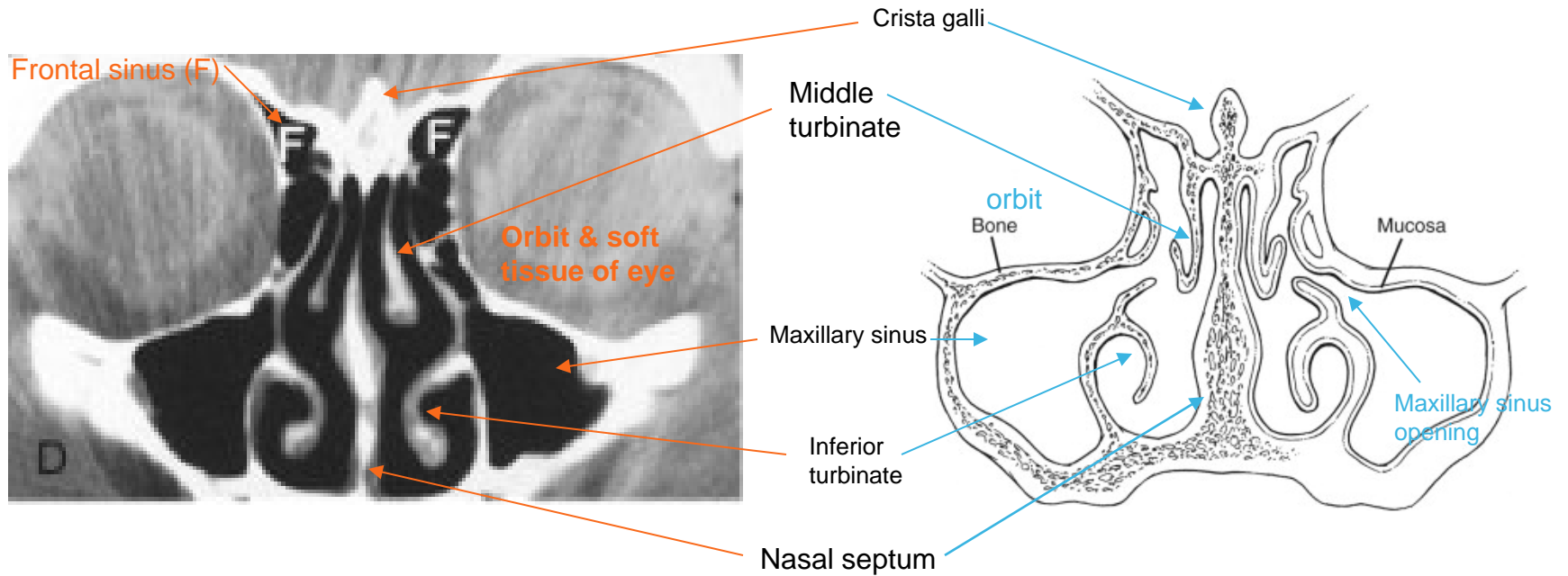
Chronic Sinusitis

- >12 weeks
- Etiology: Often not infectious, however bacterial profile differs from acute
 - Staph aureus, coag-negative staph, anaerobes, polymicrobial infections, pseudomonas
 - Culture-directed antimicrobial therapy is essential
 - Can also be fungal
- Symptoms: *Chronic* Purulent nasal drainage + facial pain/pressure + nasal obstruction + hyposmia
- Diagnosis: endoscopic evidence of polyps, purulent mucus from sinuses, CT sinus findings



Endoscopic view demonstrating polypoid mucosa

SINUS ANATOMY

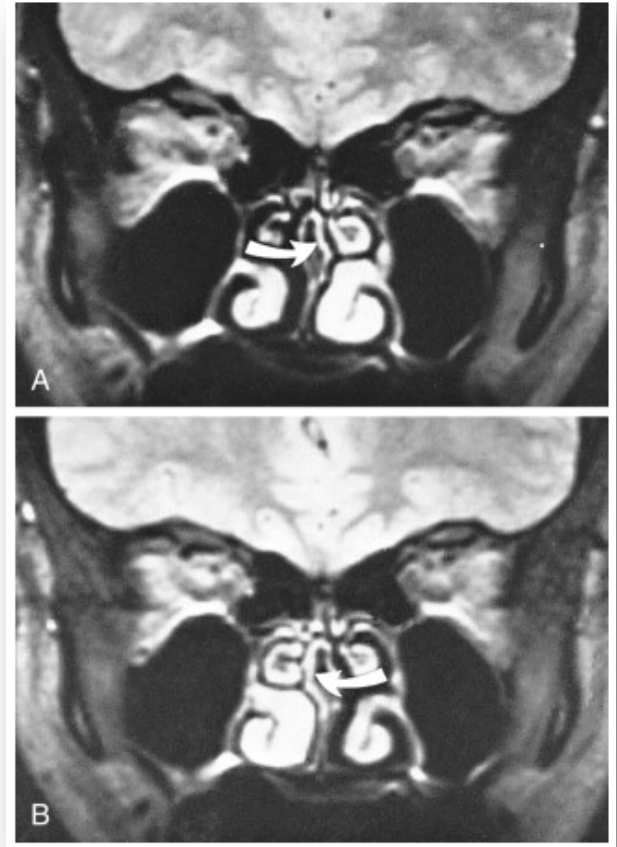


Coronal slices through Nose/sinuses: **CT scan** and **Diagram of bony architecture**)

ANATOMY & PHYSIOLOGY

- Paranasal sinuses lined by pseudostratified ciliated columnar epithelium with mucus-secreting goblet cells
- **Nasal Cycle:**
 - Normal alternating cyclic variation in thickness of nasal cavity mucosa
 - Each side alternately demonstrates mucosal swelling
 - Alternates from side-to-side throughout the day, cycling more than once per hour
- **Samter triad: Asthma + nasal polyps + aspirin sensitivity**

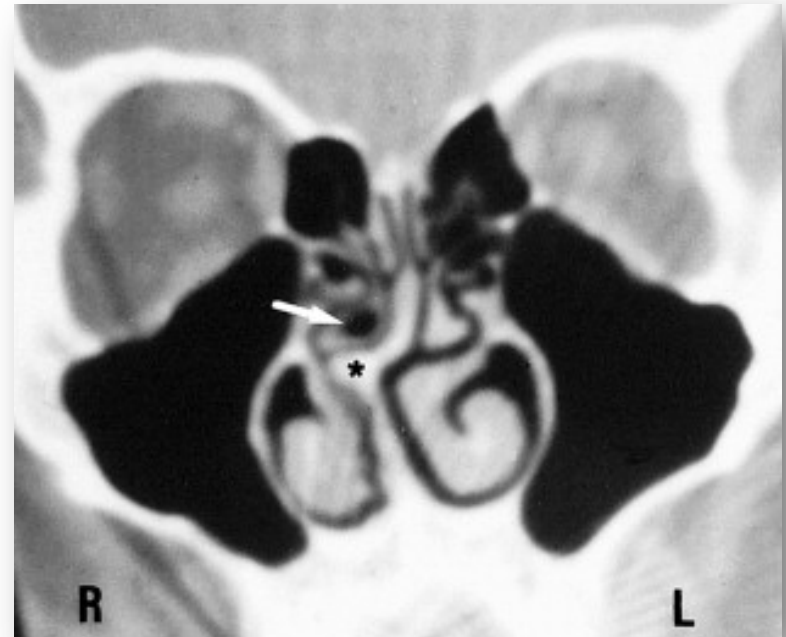
MRI in coronal plane- two images of a normal healthy patient taken 30 minutes apart, demonstrates the nasal cycle



ANATOMY & PHYSIOLOGY

Factors that predispose patients to Rhinosinusitis:

- Impaired Mucociliary clearance: allows for blockage of sinus drainage passages
 - Viral upper respiratory tract infections
 - impaired clearance causes blockage, which allows bacteria to proliferate, causing mucosal thickening, worsening obstruction
 - Cystic fibrosis, ciliary dyskinesia (Kartagener's), immunodeficiency
- Allergies - cause mucosal inflammation
- Anatomic abnormalities
 - Septal deviation, abnormalities of concha/turbinates, or sinus openings



Coronal CT scan depicting nasal septal deviation to the right and right septal spur (*)

TREATMENT OF SINUSITIS

-Acute Sinusitis

- **Antibiotics**
 - Amoxicillin or Augmentin x 10 - 14 days
 - If PCN allergic, use fluoroquinolone or clindamycin
- The following are useful adjuncts:
 - Topical nasal steroids
 - Fluticasone, flunisolide, mometasone
 - Nasal Saline Irrigation: sinus rinse/lavage
 - Antihistamines- sometimes useful in patients with AR

-Chronic Sinusitis

- **Multi-Rx Therapy**
- Antibiotics
 - Culture-directed
 - Chronic therapy with long-term macrolide for frequent recurrences
 - Broad spectrum x 3 weeks for flares
 - Augmentin (amox-clav), 2nd-3d generation cephalosporins, Clindamycin
- Nasal steroids
- Nasal saline irrigation
- Oral steroids- for patients with Polyps
- Surgery for fungal sinusitis, significant nasal polyposis, or refractory disease

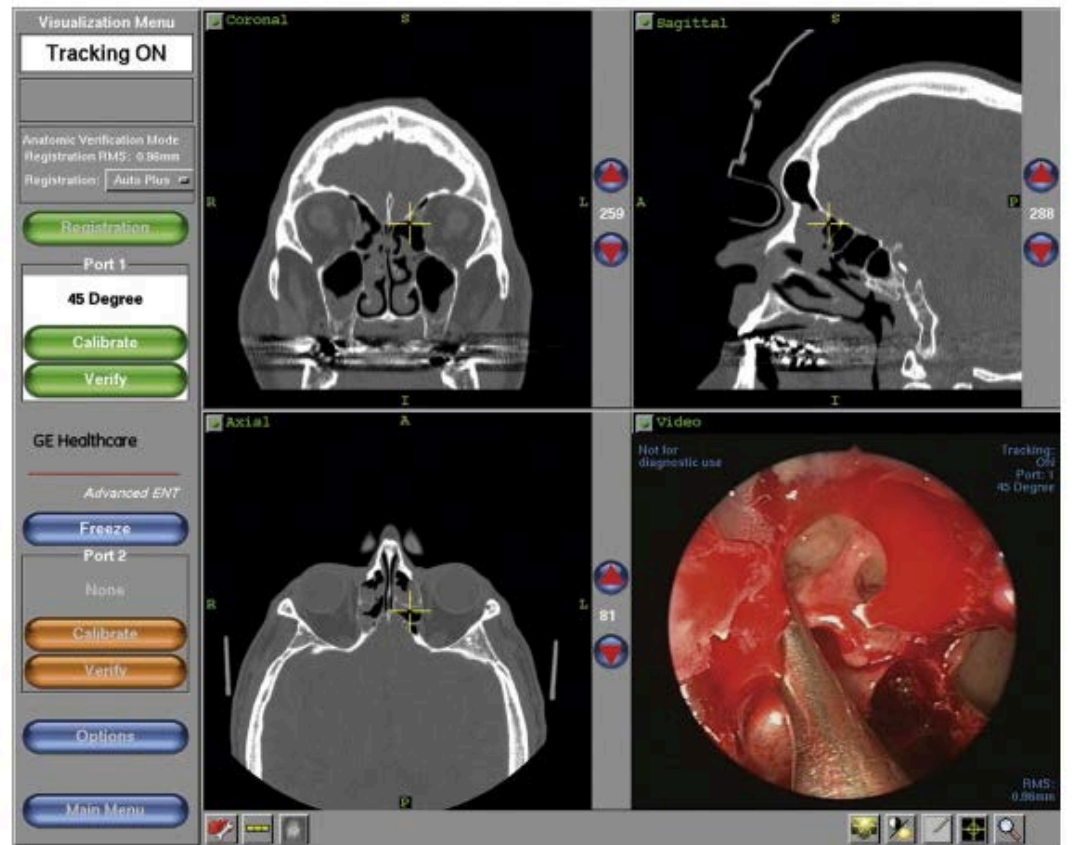
SINUS SURGERY

- **Indications:**
 - Sinonasal polyposis
 - Goal of surgery to remove nasal obstruction to allow for delivery of medical therapy.
 - Surgery is adjunctive and polyps recur without medical regimen
 - Chronic rhinosinusitis after failure of maximal medical therapy
 - Recurrent acute rhinosinusitis
 - 4 or more episodes refractory to medical therapy with documentation of endoscopic disease or CT sinus with evidence of disease while symptomatic
 - Acute complications of sinusitis (orbital or intracranial)
 - Fungal sinusitis
 - Allergic fungal sinusitis, fungal ball
 - Invasive fungal sinusitis: surgical emergency, occurs in immunocompromised patients
 - Mucocele: epithelium-lined, mucous containing sacs filling usually frontal or ethmoid sinuses and are often expansile, causing bone erosion
 - Surgery to prevent intracranial/orbital complications

ENDOSCOPIC SINUS SURGERY

-Functional Endoscopic Sinus Surgery (FESS)

- Endoscope and endoscopic tools used to operate on the sinus cavities through the nose
- Image-guidance: preoperative CT sinus loaded to system and synced to patient's head position using sensors/probes
 - Gives 3-dimensional representation of location within sinus during surgery
 - FESS can often be done without image-guidance, however are often used for complex cases or teaching



TAKE HOME POINTS

- Key to proper treatment of nasal and sinus disease lies in obtaining the correct diagnosis
- Rhinosinusitis is treated first with medical management and then, if ineffective or complications, pursue surgical management
- Mainstay of therapy for allergic rhinitis is nasal steroids. Sinusitis patients are likely to benefit as well, especially those with chronic disease and polyposis
- Chronic Rhinosinusitis should be formally diagnosed with diagnostic criteria, including CT scan of paranasal sinuses prior to referral to Otolaryngology

RESOURCES

Amir I, Yeo JC, Ram B. Audit of CT scanning of paranasal sinuses in patients referred with facial pain. *Rhinology*. 2012 Dec;50(4):442-6.

Bailey BJ, Johnson JT. *Otolaryngology – Head & Neck Surgery*. 4th ed. Lippincott Williams 2006.

Flint. Cummings *Otolaryngology: Head & Neck Surgery*, 5th ed. 2010 Mosby/Elsevier.

Leung RM, Chandra RK, Kern RC, Conley DB, Tan BK. Primary care and upfront computed tomography scanning in the diagnosis of chronic rhinosinusitis: A cost-based decision analysis. *Laryngoscope*. 2013 Aug 5

Patel ZM, Kennedy DW, Setzen M, Poetker DM, DelGaudio JM. "Sinus headache": rhinogenic headache or migraine? An evidence-based guide to diagnosis and treatment. *Int Forum Allergy Rhinol*. 2013 Mar;3(3):221-30. doi: 10.1002/alr.21095. Epub 2012 Nov 5.

Settipane RA, Kaliner MA. "Chapter 14: Nonallergic Rhinitis". *American Journal of Rhinology & Allergy- Understanding Sinonasal Disease: A Primer for Medical Students and Residents*. Supplement I May-June 2013.

Kari E, DelGaudio JM. Treatment of sinus headache as migraine: the diagnostic utility of triptans. *Laryngoscope*. 2008 Dec;118(12):2235-9.

ACKNOWLEDGEMENTS

Thank you to Christian Stallworth, MD for overseeing this project and providing advisory support.

Photo credits: Thank you to Megan M. Gaffey, MD and Lauren Thomas for providing physical exam photo

Editing and input: Philip Chen, MD