

# TRACHEOSTOMY

THE SURGICAL AIRWAY

By: Christine B. Taylor, MD

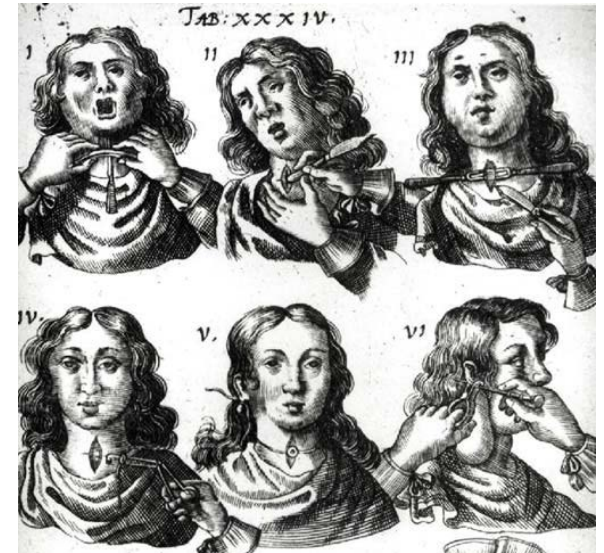# LEARNING OBJECTIVES

After reviewing this module, the student will have the ability to:

- Describe indications for tracheostomy placement
- Become familiar with basic anatomy encountered in establishment of surgical airway
- Understand the various types and parts of standard tracheostomy tubes
- Name some complications of tracheostomy placement

# HISTORY

- Earliest tracheotomies performed may date back as early as 2000BC in Hindu writings, which describe the healing of throat incisions
- Imhotep and the Egyptians used tracheostomy to resolve upper airway obstruction
- Alexander the Great was reported to have cut a soldier's trachea open to prevent him from suffocating on an aspirated bone in 300s BC
- Creation of a surgical airway described several times since 1500s, but no standard operative procedure or specialized equipment until 20th century
- 1799: George Washington died of upper airway obstruction due to bacterial epiglottitis in the presence of 3 physicians, one of whom was aware of described procedure of tracheostomy, but declined to perform because he felt it was a futile effort and was wary of performing this 'novel' procedure on the president



# HISTORY

## Development of the tracheostomy tube:

- 1869: German Physician, Dr. Trendelenburg created the first cuffed tracheostomy tube
- 1885: American pediatrician and obstetrician, Joseph O'Dwyer created a series of metal tracheal tubes after witnessing the mutilating effect of hasty tracheostomies. He also advanced the practice of oral intubation with his instruments

## Modern Tracheostomy

- First successful tracheostomy in U.S. 1852
- 1909: Chevalier Jackson described safe surgical technique in landmark paper that is still the foundation for current practices

# CASE PRESENTATION

Mr. S is a 54 year old morbidly obese male (BMI 60) who presents to the emergency department in respiratory distress. He has increased work of breathing and is saturating in the 80% range.

A brief history reveals long-standing obstructive sleep apnea with very poor compliance to his CPAP. In the ER, the blood gas demonstrates significant hypercapnea.

Patient is intubated in the ER and admitted to the Medical ICU. After 2 days in the MICU, the pulmonologist determines that patient is unable to be extubated due to known OSA and new diagnosis of obesity hypoventilation syndrome.

**Is this patient a candidate for tracheostomy at this time?**

# QUESTION

Which of the following is NOT an indication for tracheostomy?

- A. Intubation/ventilator dependence for 2 days or longer
- B. Severe facial trauma requiring surgical repair
- C. Neurologic deficit of chest wall/diaphragm muscles
- D. Upper airway obstruction such as mass or tumor
- E. OSA

# QUESTION

Which of the following is NOT an indication for tracheostomy?

- A. Intubation/ventilator dependence for 2 days or longer
- B. Severe facial trauma requiring surgical repair
- C. Neurologic deficit of chest wall/diaphragm muscles
- D. Upper airway obstruction such as mass or tumor
- E. OSA

# INDICATIONS

## Ventilator Dependence

- Prolonged Intubation: patients requiring ventilator support for longer than 7 days. These patients often fail spontaneous breathing trials or failed extubation attempts during that time period.
- Inability to protect airway (stroke or neuro-trauma patients) or inability to generate respirations (diaphragm paralysis or paresis from neuromuscular disorders such as Guillan Barre)

## Upper Airway Obstruction

- Trauma: bleeding, fractures, injuries to upper aerodigestive tract
- Masses: Head and Neck cancer, congenital anomalies, severe infections

**OSA and Obesity Hypoventilation Syndrome:** failure of CPAP and other medical therapies



# TYPES OF SURGICAL AIRWAY

- **Cricothyroidotomy**
  - Emergency (often bedside) procedure
  - Temporary surgical airway
    - Requires revision/conversion to tracheostomy
    - Airway created by incision through cricothyroid membrane (median cricothyroid ligament)
- **Tracheostomy**
  - Open tracheostomy (in operating room)
  - Percutaneous tracheostomy (bedside, usually in ICU)

# ANATOMY

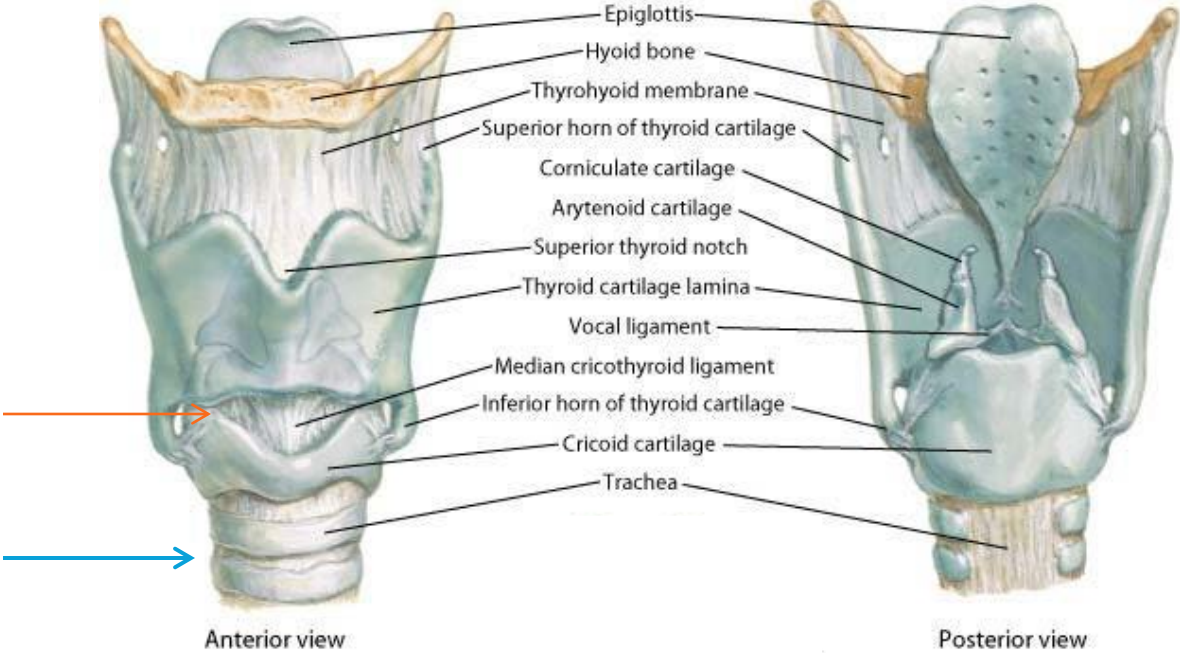
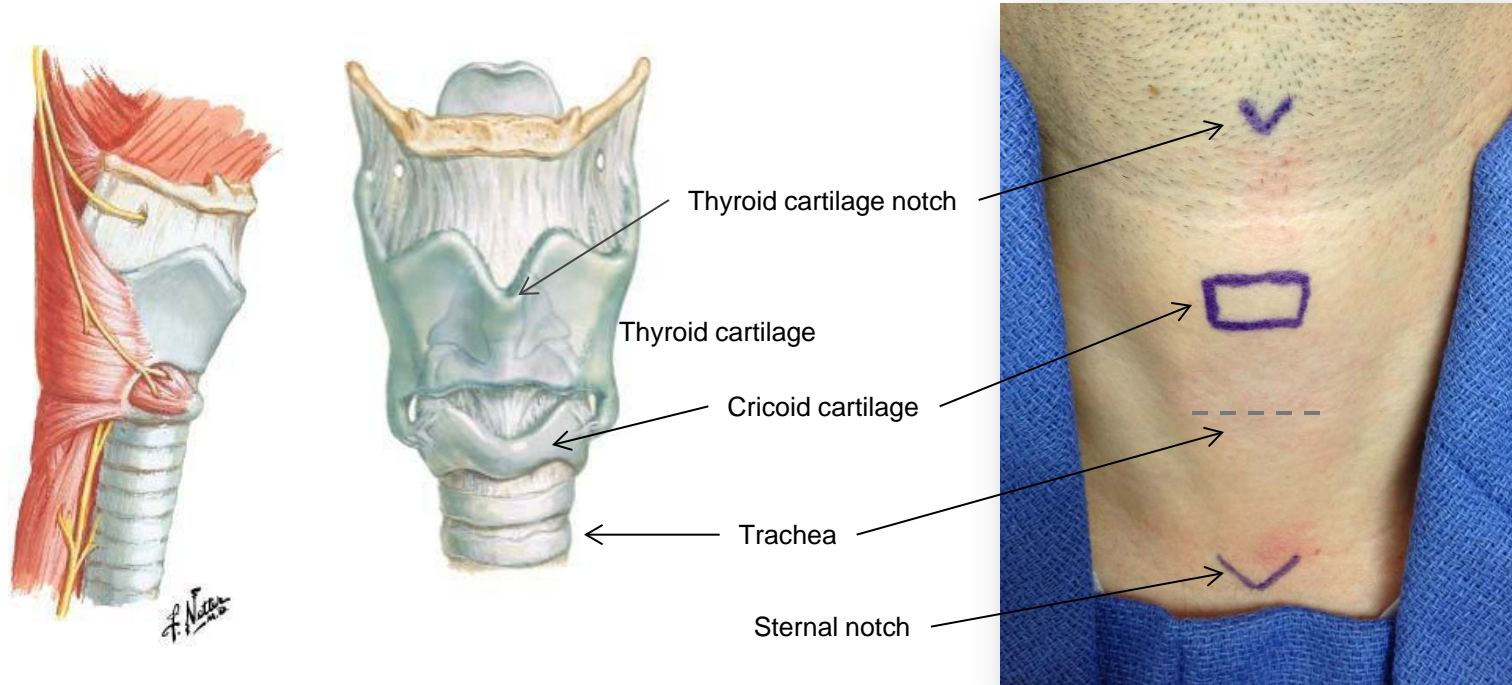


Photo: Netter's Atlas of Human Anatomy

# IMPORTANT ANATOMY



Tracheostomy placement between tracheal rings, typically between the 2<sup>nd</sup> & 3<sup>rd</sup> tracheal rings

# FEATURES OF TRACH TUBES

## Types of Tracheostomy Tubes

- Trach tubes can be made of Metal (Jackson), PVC (Shiley\*\*), Silicone (Bivona)
- Fenestrated vs. unfenestrated: Fenestrated tubes have small hole ('fenestra') to allow air to pass through tube, particularly up from lungs through vocal cords to allow phonation
- Cuffed vs. uncuffed: Cuffed tube for patient requiring positive pressure ventilation
- Size determined by tube diameter- corresponds to trachea size; standard adult size #6

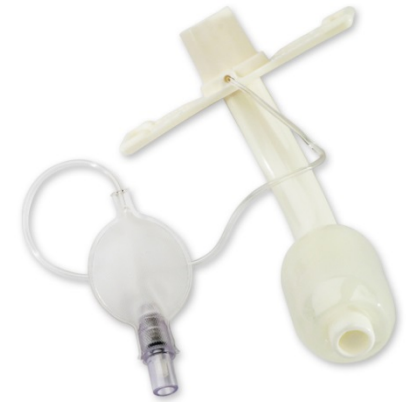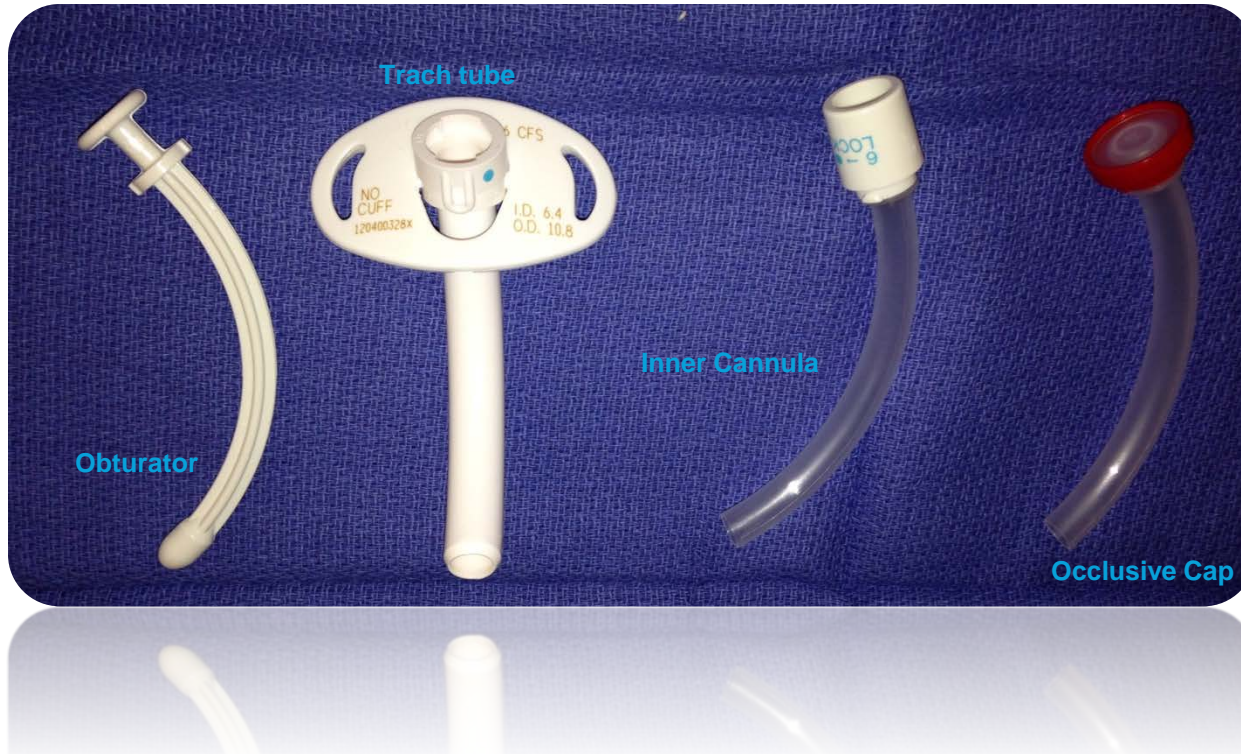## Parts of the Trach tube

- Outer cannula: keeps tracheostomy stented open
- Inner cannula: can be removed for cleaning and replaced
- Obturator: to introduce trach in a nontraumatic fashion
- Face plate: sits flush against neck, is often sutured initially
- Balloon/cuff: can be inflated or deflated depending on need for ventilation

\*\* Shiley = most commonly used trach tube at our institution

# TRACHEOSTOMY TUBES

#6 Shiley uncuffed, unfenestrated (CFS) trach and parts



Cuffed, unfenestrated




Uncuffed, fenestrated



# TRACH CARE

- **Routine Trach care:**
  - Humidification +/- supplemental oxygen
  - Suctioning: trach kits with soft suction catheter, brushes, saline for cleaning
  - Removal of inner cannula for cleaning or in case of plugging
  - Let cuff down on a cuffed trach whenever patient not requiring positive pressure ventilation (CPAP, BiPap, ventilator) to prevent pressure necrosis
  - Routine trach care important for preventing mucous plug
- **Passy-Muir Speaking Valve**
  - One way valve that can be placed over trach tube
  - Allows air in for respiration but prevents air escape from trach tube to direct air upward to pass through vocal folds for speech generation



**\*If trach tube comes out, immediately replace using obturator to reintroduce tube through stoma**

# POSTOP TRACH MANAGEMENT

- **Trach changes**
  - First trach tube change should occur between postop day 5-7
    - Remove any sutures
    - If patient no longer requiring positive pressure ventilation (PPV), switch out for uncuffed trach tube
    - If patient still requiring PPV, may leave cuffed tube in place
    - May downsize trach tube to smaller size once patient tolerating uncuffed tube off vent and able to use passy-muir valve or finger occlusion for speech
- **Decannulation**
  - Sequentially downsize trach to smaller diameter tube (down to #4 shiley)
  - Patient should undergo capping trial over several days to demonstrate that patient is able to breathe with trach tube plugged
  - Once able to tolerate capping trial, may remove trach tube (decannulate) and let wound heal closed

# CASE PRESENTATION

Mr. P is a 24 year old male status post unhelmeted motorcycle crash 7 days ago.

Patient was intubated on arrival to the trauma bay for unresponsiveness/airway protection, and was then taken to the operating room by neurosurgery for decompressive hemicraniotomy.

Patient has been in the Intensive Care Unit since surgery, intubated, and has failed multiple spontaneous breathing trials and also failed a single trial of extubation in which he required prompt reintubation. The ICU team has been able to wean the ventilator settings to minimal oxygen requirements and positive end-expiratory pressure (PEEP) of 5.

You determine that this patient meets criteria for tracheostomy placement. After discussing the plan with the family, you obtain informed consent.



# QUESTION

Match the complication with the associated underlying cause(s) or associated factors

- |  |                                   |
|--|-----------------------------------|
| 1. Mucous plug                                   | A. Trach tube balloon             |
| 2. Tracheoesophageal fistula                     | B. Trach care                     |
| 3. Ulceration/necrosis of trachea                | C. Surgical procedure             |
| 4. Tracheoinnominate fistula, hemorrhage         | D. Anatomy                        |
| 5. Loss of airway after accidental decannulation | E. Failure of maturation of tract |
|  | F. Ill-fitting trach tube         |

# QUESTION

Match the complication with the associated underlying cause(s) or associated factors

- |  |      |                                   |
|--|------|-----------------------------------|
| 1. Mucous plug                                   | B    | A. Trach tube balloon             |
| 2. Tracheoesophageal fistula                     | C, F | B. Trach care                     |
| 3. Ulceration/necrosis of trachea                | A, F | C. Surgical procedure             |
| 4. Tracheoinnominate fistula, hemorrhage         | C    | D. Anatomy                        |
| 5. Loss of airway after accidental decannulation | E, B | E. Failure of maturation of tract |
|  |      | F. Ill-fitting trach tube         |

# REFERENCES

Bailey BJ, Johnson JT. Otolaryngology – Head & Neck Surgery. 4<sup>th</sup> ed. Lippincott Williams 2006.

Flint. Cummings Otolaryngology: Head & Neck Surgery, 5th ed. 2010 Mosby/Elsevier.

Szmuk et al. A brief history of tracheostomy and tracheal intubation, from the Bronze Age to the Space Age. Intensive Care Med (2008) 34:222–228 DOI 10.1007/s00134-007-0931-5

Netter Atlas of Anatomy – Accessed via The Netter presenter : human anatomy collection. edited by John T. Hansen. Elsevier 2010.

Photo credit: Covidien website

<http://www.covidien.com/rms/pages.aspx?page=OurProducts/Tracheostomy>

# ACKNOWLEDGEMENTS

Thank you to Christian Stallworth, MD for overseeing this project and providing advisory support.

Photo credits: Thank you

C. Blake Simpson, MD and Jeanne Hatcher, MD for providing photo from laryngology clinic

Matthew Stevens, MD for photo of neck landmarks

Editing and input: John Morehead, MD, Matthew Stevens, MD